



Patient

NHS No

D.O.B.

Patient Ref

Reason

Routine

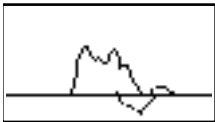
Outcome

Aneurysm, Occlusion, Bowel gas, Poor images, patient habitus

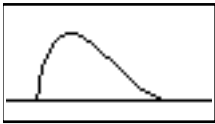
Right

170

1.00



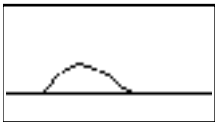
turbulent



Reduced



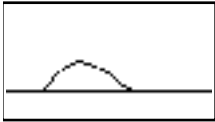
Weak



Weak

100

0.59



Weak

Brachial

Common Femoral

High Thigh

Low Thigh

Popliteal

High Calf

Peroneal

Anterior Tibial

Reduced

140

0.82

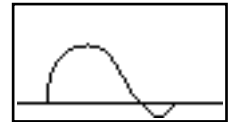
Posterior Tibial

Dorsalis Pedis

Toe Pressure

Post Exercise

Left



Notes

RIGHT LOWER LIMB ARTERIAL DUPLEX ASSESSMENT

The abdominal aorta appears aneurysmal with dimensions: Outer-to-outer LS =4.5cm, AP =4.5cm; Inner-to-inner LS =4.0cm, AP = 4.0cm. Increase in AAA dimensions observed since previous assessment. Bi/triphasic waveforms and PSV 43cm/s identified in abdominal aorta.

RIGHT

CIA - obscured by overlying bowel gas/dressing over umbilicus, therefore cannot exclude significant disease in this vessel.

Assessed by

Lukasz Koprowski

Checked by

Patient

NHS No

D.O.B.

Patient Ref

EIA - biphasic waveforms and PSV 100cm/s identified in proximal vessel, which is patent. Mid-distal EIA is partially obscured but is at least moderately diseased with biphasic waveforms and PSV 196cm/s.

CFA - patent proximally, triphasic waveforms, PSV 161cm/s. Focal (~1cm), moderate disease at mid vessel, turbulent triphasic waveforms, PSV 330cm/s. Distally the velocities decrease to 90cm/s triphasic.

PFA - origin not clearly visualised, but proximal vessel appears patent, triphasic waveforms and PSV 50cm/s.

SFA - occluded from its origin with extensive mixed, dense and calcified disease seen in vessel lumen. No evidence of SFA re-constitution seen above knee level.

POPA - flow re-forms in to very proximal POPA. Diffuse mild/moderate disease distally with weak/reduced monophasic waveforms and PSV 36cm/s. TPT is patent; origins of two vessel run-off identified.

PTA, ATA & PerA - all patent along length with weak monophasic waveforms and PSV 9-17cm/s at ankle (PTA appears calcified with intermittent flow seen).

Bilateral, resting ABPIs are significantly reduced on the right and within normal limits on the left.

